

# Young girl with psychosis, cognitive failure and seizures

Psychiatric symptoms combined with neurological disturbances should always arouse suspicion that the cause may be organic. We describe a young patient whose examination revealed a recently described condition for which there are precise diagnostics and in many cases effective treatment.

## Imer Önder Slettedal\*

Department of Adolescent Mental Health  
Centre for Child and Adolescent Mental Health  
Oslo University Hospital, Ullevål

## Hilde Margrete Dahl

Inger Sandvig  
Department of Clinical Neurosciences  
for Children,  
Women and Children's Division  
Oslo University Hospital, Ullevål and  
Rikshospitalet

## Josep Dalmau

Department of Neurology  
University of Pennsylvania  
Philadelphia, PA  
USA

## Petter Strømme

petter.stromme@medisin.uio.no  
Department of Clinical Neurosciences  
for Children,  
Women and Children's Division  
Oslo University Hospital, Ullevål

### \* Current address:

Department for Personality Psychiatry  
Oslo University Hospital, Ullevål

A girl of school age was admitted after left-sided facial seizures and seizures in her left arm, accompanied by reduced consciousness. In the three weeks leading up to hospitalisation she had been telling her parents that she felt «funny». Her parents and teachers had observed progressive personality and behavioural changes in the form of mood swings, anxiety and aggression, disrupted sleep with nightmares and involuntary movements of her hands and face. She had previously been healthy and had followed the normal vaccination programme. Her psychomotor development had been normal and her academic performance had been good until the onset of symptoms.

Behavioural change in children is non-specific, but when accompanied by neurological symptoms such as focal seizures, organic brain changes spring to mind, for example caused by a tumour or encephalitis.

On admission we found postictal inversion of the left plantar reflex, otherwise equal tempo and power in the extremities on both sides. She was disoriented, afebrile, with no neck stiffness or swollen joints, and there was no skin or facial rash. Blood tests showed a leukocyte count of  $3.4 \cdot 10^9/l$  ( $4.5-14.0 \cdot 10^9/l$ ), the C-reactive protein (CRP) level was  $< 0.5$  mg/l ( $< 10$  mg/l), SR 4 mm/t ( $< 10$  mm/t), B lactate 1.6 mmol/l ( $< 2.5$  mmol/l), B glucose 4.4 mmol/l ( $3.5-6.0$  mmol/l) and S creatinine 45 mmol/l ( $35-60$  mmol/l). The cerebrospinal fluid (CSF) showed a total protein level of 1.0 g/l ( $< 0.4$  g/l), a leukocyte count of  $88 \cdot 10^6/l$  ( $< 4 \cdot 10^6/l$ ), lactate 1.2 mmol/l ( $< 2.5$  mmol/l) and glucose 3.5 mmol/l. The CSF glucose: blood glucose ratio was 0.8 ( $> 0.67$ ). The cerebrospinal fluid protein electrophoresis was normal. The EEG showed slow rhythms and some epileptic activity, particularly above the right hemisphere (Fig. 1). Magnetic resonance imaging (MRI) of the brain and medulla spinalis (with and without contrast medium) showed no tumour or signal changes in the parenchyma or meninges at T2-weighting.

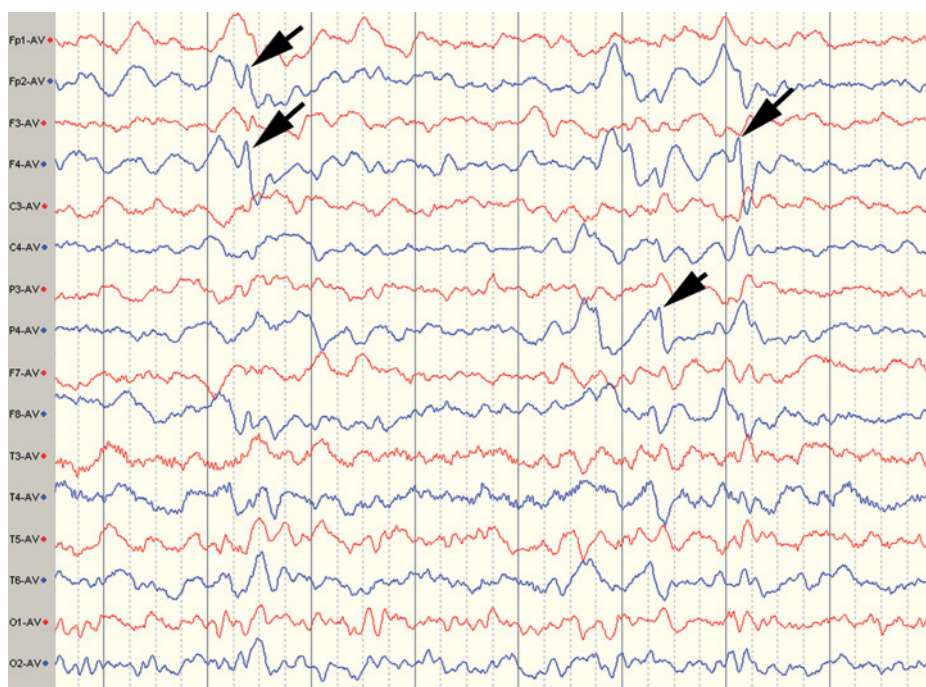
Clinically and according to EEG, the girl suffered from encephalitis. This was supported by an increase in the total protein level and leukocyte count in the CSF. Metabolic, neurodegenerative and immunological diseases were also considered. Normal concentrations of serum lactate and spinal lactate normally exclude mitochondrial diseases. Normal glucose levels in serum and CSF, and a normal CSF glucose: blood glucose ratio, virtually ruled out a congenital glucose transport defect in the blood-brain barrier (GLUT1 defect). A negative family anamnesis rendered Huntington's disease unlikely. Systemic lupus erythematosus (SLE) may result in psychiatric and neurological disorders, but normal ESR and the lack of any skin, joint or renal changes made this diagnosis improbable (1). Rasmussen's encephalitis was also considered. This is an immunologically conditioned epileptic encephalitis with spastic hemiparesis, asymmetric EEG changes and cerebral hemia-

trophy (2). The condition often starts with myoclonic seizures while the mental changes occur later, i.e. the opposite order of progression from that found in our patient.

Symptomatic treatment was initiated with Carbamazepine and Chlorpromazine. The patient was afebrile, had a normal blood leukocyte count and normal CRP, which suggested that there was no bacterial infection. Due to the serious clinical picture, the patient was nevertheless given broad-spectrum coverage with Ceftriaxone and Ampicillin administered intravenously against *Borrelia* and *Listeria*. Acyclovir was also administered, even though the laboratory data gave no indication of a herpes virus infection. Later microbiological tests showed no indication of infection caused by any of these agents, nor infections caused by Epstein-Barr, varicella, rubella or rabies viruses, or *Toxoplasma gondii*. Tests for antibodies against *Mycoplasma pneumoniae* were non-conclusive. Variant Creutzfeldt-Jakob Disease (vCJD) was improbable due to the brief case history and the fact that no signal changes in the brain appeared on the MRI scan (3); also, the CSF tested negative for 14-3-3 protein. This protein is a marker for nerve cell destruction, especially in sporadic Creutzfeldt-Jakob Disease (4). Also, the CSF showed normal values for the glial cell marker GFAP (glial fibrillary acidic protein) and the nerve cell markers NFLP (neurofilament protein) and tau protein, which again suggested that there was no form of active brain tissue destruction. Cerebral magnetic resonance spectroscopy (MRS) showed a normal metabolic pattern, which was also an indication against metabolic/ neurodegenerative disease (5).

The patient's psychiatric symptoms of anxiety, aggressive behaviour and delusions were constantly getting worse, despite treatment with antipsychotics. Irrespective of seizures she suffered fits of rage with self-injury and unmotivated laughter. She was suffering from global cognitive failure, dyspraxia, mutism, insomnia, dystonia and catatonia, as well as autonomic nervous system disorders in the form of dilated pupils and tachycardia. She developed difficulties with swallowing and started dribbling, became doubly incontinent, required tube feeding and was largely bedridden.

Given such prominent psychiatric symptoms, combined with pathological findings in the



**Figure 1** Two weeks after admission, the EEG shows slow activity, most pronounced in the right hemisphere (blue curve) and isolated epileptic discharges (arrow) in the right hemisphere. The patient was medicated with prednisolone, chlorpromazine, risperidone, chloral hydrate and carbamazepine. An earlier examination without medication showed the same slow rhythm, but no epileptiform discharges.

EEG and CSF, limbic encephalitis should be considered. This is a heterogenous condition caused by autoimmune factors and is often associated with malignant disease (6). In the majority of cases of limbic encephalitis, signal changes will be expected in T2-weighted MRI, but the absence of such changes (as in our patient) does not rule out the diagnosis.

Nevertheless, we interpreted the condition to be immune-mediated and treated the patient with steroids and intravenous immunoglobulin from week 3 to week 7 in hospital. Due to unsatisfactory clinical results, plasmapheresis was initiated in week 9. This resulted in immediate improvement followed by gradual recovery. She was discharged

after five months and could go back to school eight months after admission. While in hospital and at later out-patient check-ups she was examined for possible malignant disease. Full body CT, MRI, positron emission tomography (PET) and abdominal ultrasound examinations, as well as repeated measurements of tumour markers in serum and urine, were normal. Neuropsychological tests 18 months after admission established that her cognitive functions continued to be weakened. Similar tests 2.5 years after admission showed better results, and after 4.5 years the results were completely normal. The patient is now healthy.

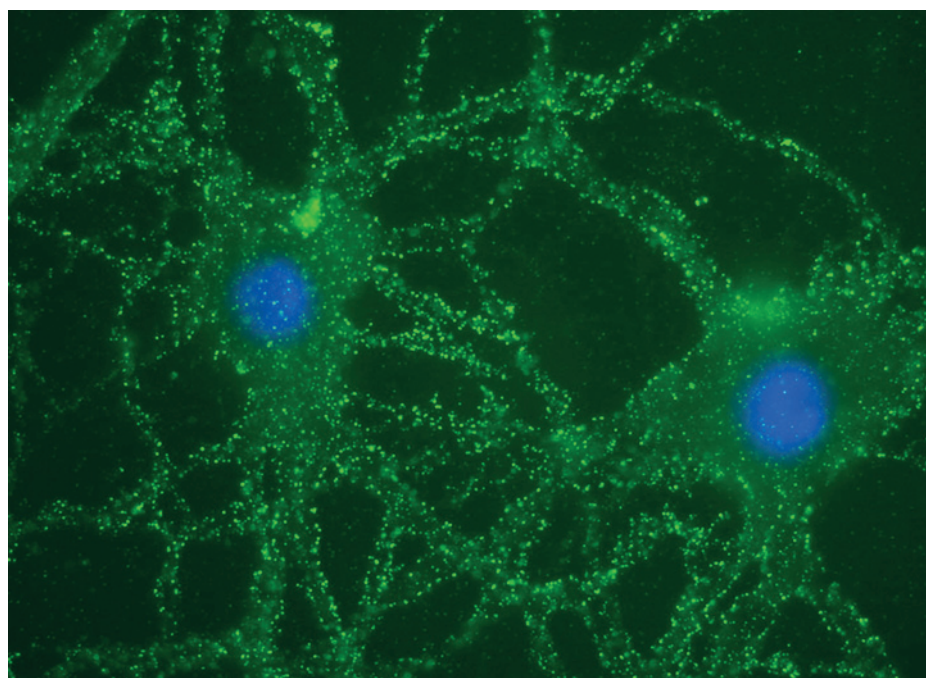
The obvious effect of plasma exchange clearly pointed towards an immune-mediated disease, but specific antibodies or other immunological markers could not be established while the patient was in hospital. Prior to the plasmapheresis, samples of the patient's CSF and serum were frozen. In the light of reports of a new type of autoimmune encephalitis (7), the frozen samples were sent to the University of Pennsylvania, USA. The analyses showed the presence of NMDA (N-methyl D-aspartate) receptor antibodies in serum and CSF (Fig 2) (8), and we therefore concluded that the diagnosis was anti-NMDA receptor encephalitis.

**Discussion**

Anti-NMDA receptor encephalitis is not entirely uncommon, and in a prospective study of 203 encephalitis patients in England, nine (4%) were found to have NMDA receptor antibodies (9). As far as we know, our patient is the first case in Norway to have had a diagnosis of anti-NMDA receptor encephalitis verified.

*Clinical picture*

Anti-NMDA receptor encephalitis differs from limbic encephalitis in that it normally develops in stages, often in five distinct phases: the prodromal phase, the psychotic phase, the non-responsive phase, the hyperkinetic phase and the gradual recovery phase (10, 11). Box 1 gives a summary of the condition's clinical picture. The majority of patients experience prodromal symptoms similar to those of a viral infection. Within a few days they present with psychiatric manifestations such as anxiety, depression, insomnia, agitation, aggression, personality changes and psychotic symptoms. Loss of short-term memory is common, but can be difficult to establish in small children. Linguistic regression with echolalia, echopraxia and mutism occurs during the non-responsive phase, which is normally followed by motor disturbances and catatonia. Instability of the autonomic nervous system gives temperature and blood pressure fluctuations, central hypoventilation, arrhythmia, sweating, increased saliva production, incontinence and obstipation. Dystonia or seizures



**Figure 2** Two neurons in a cell culture from a rat hippocampus, immunostained with cerebrospinal fluid from a patient. The multiple fluorescent green points on the cell surface indicate the presence of NMDA receptor antibodies. The nerve cell nuclei are stained blue using DAPI [4',6'-diamidino-2-phenylindole]. The figure is taken from Lancaster et al. [8] and is reproduced with their permission.



**Box 1****Symptoms and indications of anti-NMDA receptor encephalitis**

- Prodromal symptoms
  - may be mistaken for viral infection
- Psychiatric manifestations
  - personality change, anxiety, agitation
  - disturbed sleep, psychotic symptoms
- Cognitive failure and dementia
  - linguistic regression, memory loss
- Motor disorders
- Seizures
- Autonomic disturbance

often lead to hospitalisation (11). Complex partial or generalised epileptic seizures may occur at any stage of the disease, but most commonly in the early stages. Status epilepticus may also occur (12).

**Pathophysiology**

Figure 3 illustrates the pathophysiological process in which antibodies block postsynaptic glutamatergic excitatory NMDA receptors (13). The clinical stages of the syndrome probably result from increasing antibody-mediated failure of NMDA receptor functions. The trigger factor for the formation of

anti-NMDA receptor antibodies is associated with neoplasm in 60 % of cases; the remainder of cases are considered idiopathic (11).

**Examination and diagnosis**

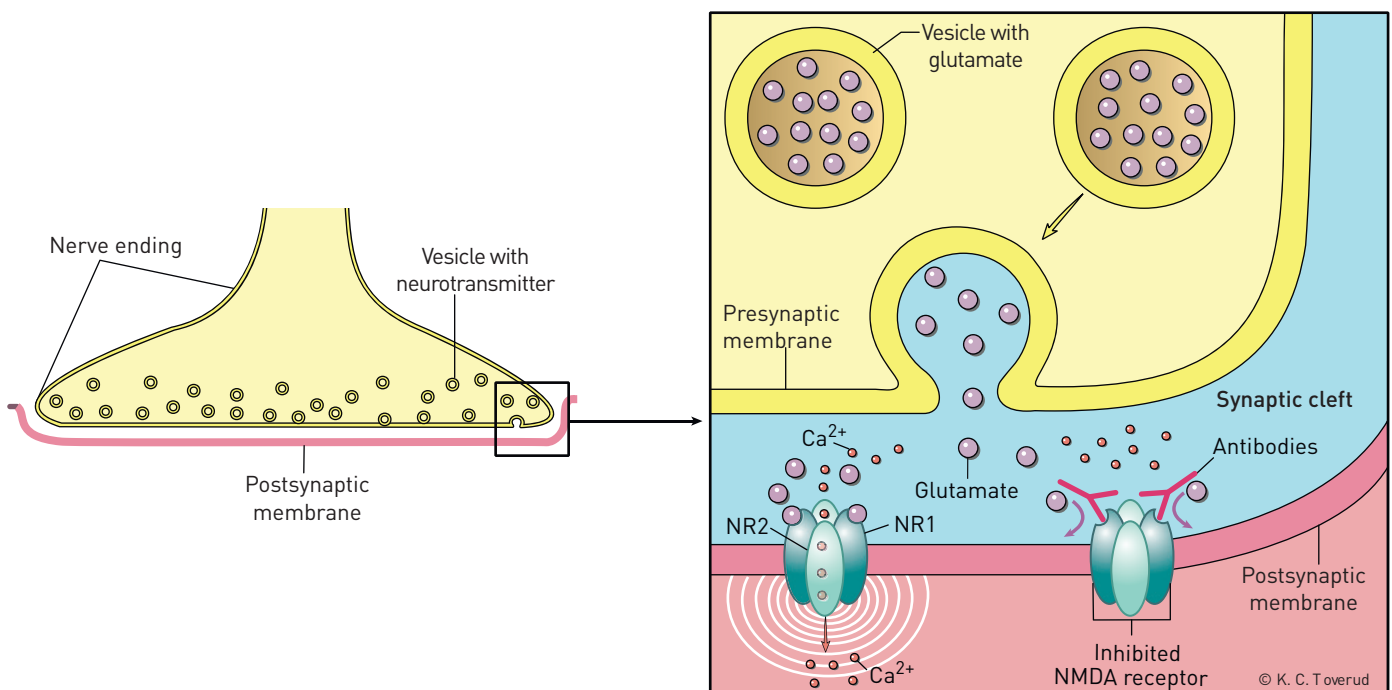
The EEG pattern is almost always pathological and shows a slow rhythm combined with epileptic activity (14). As in the case of our patient (Fig 1), the rhythm change can occur relatively unilaterally (15). In the majority of cases, there are pathological findings in the CSF; these include a moderately increased leukocyte count and/or a slightly increased total protein level, and sometimes oligoclonal bands (11). MRI scans of the central nervous system show pathological changes in half the patients, and T2-weighted examination or FLAIR (fluid attenuated inversion recovery) examination can show modest hyperintensity in the temporal lobes, the cerebellum, the basal ganglia, the brain stem and sometimes the spinal cord (11). The diagnosis can be verified by findings of specific NMDA receptor antibodies in the CSF and serum. (Analyses are performed at Haukeland University Hospital's neurology and rheumatology laboratory in Bergen.) Patients should be examined with a view to the presence of an underlying tumour. The incidence of neoplasm increases in patients over 18 years of age. In women, teratoma of the ovary is the most frequently associated tumour. Examinations relevant for patients with suspected anti-NMDA encephalitis are summarised in Box 2.

**Box 2****Diagnostics for anti-NMDA receptor encephalitis**

- Cerebrospinal fluid
  - slightly increased cell count and protein level
- Cerebral MRI with T2-weighting
  - signal increase in the temporal lobes (50 %)
- EEG
  - slow rhythm (may be unilateral)
  - epileptic activity (often modest)
- NMDA receptor antibodies confirm the diagnosis
  - established in cerebrospinal fluid and/or serum
- Tumour, especially teratoma (of the ovary), should be ruled out

**Differential diagnoses**

Anti-NMDA receptor encephalitis is probably the second most common immune-mediated type of encephalitis, second only to acute disseminated encephalomyelitis (ADEM) which is typically characterised by high signal areas in the brain and spinal cord in T2-weighted MRI scans (16). Other types of encephalitis are caused by antibodies against a number of other receptors, and ion



**Figure 3** Schematic illustration of NMDA [N-methyl D-aspartate] type glutamate receptors in the brain. The NMDA receptor consists of two NR1 and two NR2 subunits and is important for synaptic «learning» through LTP [long term potentiation]. The enlarged figure shows a normally functioning receptor to the left and an inhibited receptor to the right. Nerve impulses pass through the synaptic cleft by glutamate being released from presynaptic vesicles and binding itself to postsynaptic glutamate receptors. The NMDA receptor, which is also dependent on glycine (not shown), becomes active only when the membrane has been partly depolarised by another glutamate receptor, the AMPA receptor (not shown), which transmits the main signal.  $Ca^{2+}$  is normally let through the NMDA receptor (the receptor to the left). This induces an intracellular signalling cascade which prepares the receptor for modifying the signalling power of the active synapse. The antibodies that cause anti-NMDA receptor encephalitis are directed towards the glutamate binding site on the NR1 subunit (receptor to the right).

channels; their manifestations may overlap with anti-NMDA receptor encephalitis (17). Some patients suffering from the early stages of anti-NMDA receptor encephalitis are first admitted for psychiatric assessment and are treated with psycho-pharmaceuticals (18). However, psycho-pharmaceuticals will not stop the development of the disease, which can progress with manifestations that are confusingly similar to malignant neuroleptic syndrome with muscle rigidity, catatonia and autonomic disorders (19). NMDA receptor antibodies were established in several patients who had previously been diagnosed with encephalitis lethargica, a condition characterised by psychiatric symptoms, insomnia and extra-pyramidal motor disturbances (20). Some children who previously have been assumed to suffer from late-onset autism or unusually early manifestations of schizophrenia have turned out to be suffering from anti-NMDA receptor encephalitis (21).

#### Treatment and prognosis

Treatment consists of immune therapy with corticosteroids, intravenous immunoglobulin and/or plasmapheresis (8, 11). If the effect is unsatisfactory, rituximab or cyclophosphamide should be considered. Any tumour should be removed. With this treatment strategy approximately 75% achieve considerable improvement; the others suffer severe neurological damage or die (11). The disease is fatal in approximately 4% of cases. The most common causes of death are arrhythmia, status epilepticus, tumour progression and complications suffered during intensive care (11, 14). Improvement in disease symptoms occurs in the opposite order of its clinical phases. Symptomatic treatment includes anti-epileptics and medication for insomnia as well as psychiatric and autonomic symptoms. Anti-NMDA receptor encephalitis normally requires hospitalisation for several months, followed by physical and cognitive rehabilitation. Recovery may take up to three years (11). Early and aggressive treatment is important for optimal cognitive functioning (22). Social behaviour and executive functions are the last to normalise. Amnesia for the illness is common. Relapse occurs in up to 25% of patients and immunosuppression is recommended for a year after the initial treatment has concluded (11).

#### Addendum

After the work on this article had commenced, a patient with psychosis and catatonia was transferred to the Paediatric Department due to suspected Neuroleptic Malignant Syndrome. The EEG clearly showed slow rhythm activity, but no epileptic discharges. The serum and CSF tested positive for NMDA receptor antibodies.

*The patient and the patient's parents have given their consent to the publication of this article. The patient referred to in the Addendum has also consented.*

*We would like to thank Inger Anette Hynås Hovden at Oslo University Hospital Ullevål's Laboratory of Clinical Neurophysiology for interpreting the EEGs.*

#### Imer Önder Stlettedal (born 1976)

is a medical doctor specialising in child and adolescent psychiatry.

The author has completed the ICMJE form and declares no conflicts of interest.

#### Hilde Margrete Dahl (born 1966)

is a Paediatrician and a Senior Consultant specialising in traumatic head injuries.

The author has completed the ICMJE form and declares no conflicts of interest.

#### Inger Sandvig (born 1953)

is a Paediatrician and a Senior Consultant specialising in epilepsy.

The author has completed the ICMJE form and declares no conflicts of interest.

#### Josep Dalmau (born 1953)

is a Research Professor at ICREA-IDIBAPS, Hospital Clinic, University of Barcelona, and an Adjunct Professor of neurology at the University of Pennsylvania's Department of Neurology. Neuroimmunology is his field of special interest. The author has completed the ICMJE form and declares the following conflicts of interest: He receives royalties from Up-To-Date, and from patents for the utilisation of Ma2 and NMDA receptors in antibody analyses. He has received grant awards from Euroimmun, the National Institute of Health (RO1NS077851 and RO1MH094741), the National Cancer Institute (RO1CA89054), and Fundació la Marató de TV3, and he has been awarded the McKnight Neuroscience of Brain Disorders Award.

#### Petter Strømme (born 1951)

is a Paediatrician, Senior Consultant and Professor specialising in neurodegeneration and the genetic causes of intellectual disability.

The author has completed the ICMJE form and declares no conflicts of interest.

#### References

1. Bader-Meunier B, Armengaud JB, Haddad E et al. Initial presentation of childhood-onset systemic lupus erythematosus: a French multicenter study. *J Pediatr* 2005; 146: 648–53.
2. Sandvig I, Tennøe B, Eriksson A-S. En ti år gammel gutt med progredierende neurologiske utfall. *Tidsskr Nor Lægeforen* 2006; 126: 779–81.
3. Heath CA, Cooper SA, Murray K et al. Validation of diagnostic criteria for variant Creutzfeldt-Jakob disease. *Ann Neurol* 2010; 67: 761–70.

4. Van Everbroeck B, Boons J, Cras P. Cerebrospinal fluid biomarkers in Creutzfeldt-Jakob disease. *Clin Neurol Neurosurg* 2005; 107: 355–60.
5. Kanavin ØJ, Strømme P. Barn med neurodegenerativ sykdom. *Tidsskr Nor Lægeforen* 2010; 130: 1489–92.
6. Storstein A, Bru A, Vedeler CA. Limbisk encefalitt—en diagnostisk utfordring. *Tidsskr Nor Lægeforen* 2007; 127: 3077–80.
7. Dalmau J, Tüzün E, Wu HY et al. Paraneoplastic anti-N-methyl-D-aspartate receptor encephalitis associated with ovarian teratoma. *Ann Neurol* 2007; 61: 25–36.
8. Lancaster E, Martinez-Hernandez E, Dalmau J. Encephalitis and antibodies to synaptic and neuronal cell surface proteins. *Neurology* 2011; 77: 179–89.
9. Granerod J, Ambrose HE, Davies NWS et al. Causes of encephalitis and differences in their clinical presentations in England: a multicentre, population-based prospective study. *Lancet Infect Dis* 2010; 10: 835–44.
10. Iizuka T, Sakai F, Ide T et al. Anti-NMDA receptor encephalitis in Japan: long-term outcome without tumor removal. *Neurology* 2008; 70: 504–11.
11. Dalmau J, Lancaster E, Martinez-Hernandez E et al. Clinical experience and laboratory investigations in patients with anti-NMDAR encephalitis. *Lancet Neurol* 2011; 10: 63–74.
12. Bayreuther C, Bourg V, Dellamonica J et al. Complex partial status epilepticus revealing anti-NMDA receptor encephalitis. *Epileptic Disord* 2009; 11: 261–5.
13. Wandinger KP, Saschenbrecker S, Stoecker W et al. Anti-NMDA-receptor encephalitis: a severe, multistage, treatable disorder presenting with psychosis. *J Neuroimmunol* 2011; 231: 86–91.
14. Dalmau J, Gleichman AJ, Hughes EG et al. Anti-NMDA-receptor encephalitis: case series and analysis of the effects of antibodies. *Lancet Neurol* 2008; 7: 1091–8.
15. Florance NR, Davis RL, Lam C et al. Anti-N-methyl-D-aspartate receptor (NMDAR) encephalitis in children and adolescents. *Ann Neurol* 2009; 66: 11–8.
16. Pavone P, Pettoello-Mantovano M, Le Pira A et al. Acute disseminated encephalomyelitis: a long-term prospective study and meta-analysis. *Neuropediatrics* 2010; 41: 246–55.
17. Vincent A, Bien CG, Irani SR et al. Autoantibodies associated with diseases of the CNS: new developments and future challenges. *Lancet Neurol* 2011; 10: 759–72.
18. Nasky KM, Knittel DR, Manos GH. Psychosis associated with anti-N-methyl-D-aspartate receptor antibodies. *CNS Spectr* 2008; 13: 699–703.
19. Neuhut R, Lindenmayer JP, Silva R. Neuroleptic malignant syndrome in children and adolescents on atypical antipsychotic medication: a review. *J Child Adolesc Psychopharmacol* 2009; 19: 415–22.
20. Dale RC, Irani SR, Brilot F et al. N-methyl-D-aspartate receptor antibodies in pediatric dyskinesic encephalitis lethargica. *Ann Neurol* 2009; 66: 704–9.
21. Creten C, van der Zwaan S, Blankespoor RJ et al. Late onset autism and anti-NMDA-receptor encephalitis. *Lancet* 2011; 378: 98.
22. Finke C, Kopp UA, Prüss H et al. Cognitive deficits following anti-NMDA receptor encephalitis. *J Neurol Neurosurg Psychiatry* 2012; 83: 195–8.

*Received 29 February 2012, first revision submitted 10 April 2012, approved 21 June 2012. Medical editor: Merete Kile Holtermann.*